

ACPWH CONFERENCE 2013

The role of manual therapy in the treatment of pelvic floor dysfunction

M. Whelan

Private Practice, Dublin, Ireland

Abstract

Pelvic floor massage has been used for many years to treat the symptoms of pelvic floor dysfunction. The literature dealing with palpation of the pelvic floor has endeavoured to demonstrate either the reliability of various techniques or a correlation with pain scores in cases of dysfunction. Manual therapy research has generally reported good results with regard to symptomatic relief for patients. However, what clinicians do and how they report it varies, leading to difficulties when comparing studies. The existing literature on the use of manual therapy techniques has tended to focus on chronic pelvic pain disorders such as interstitial cystitis, but clinically, pelvic floor musculoskeletal dysfunction seems to extend across the spectrum of all urogynaecological disorders. This paper attempts to label the techniques that can be applied to the pelvic floor myofascial system, and provide a brief overview of the application of these approaches to a population with pelvic organ prolapse (POP). The background to a research study evaluating the effect of manual therapy on the levator plate in women with POP is provided, although the main findings are not reported in this paper.

Keywords: manual therapy, palpation, pelvic floor dysfunction.

The beginning of manual therapy

It was George Thiele who first gave a detailed account of manual therapy for the pelvic floor. In his original description of this technique (Thiele 1937), he reported a personal series of 31 cases of coccygodynia (i.e. coccydynia) and pelvic floor musculature spasm in which 19 (61.3%) individuals were cured and 11 (35.5%) were improved (according to undefined criteria) after transrectal massage. Using the same technique, Thiele (1937) combined his data with figures provided by eight other proctologists, and reported a 93.7% rate of cure or improvement in a total of 80 patients. In this study, treatment consisted of an average of 11 treatments over approximately 11 weeks. Thiele (1963) further described coccydynia in a review based on 324 case records. The symptoms included pain localized to the lower sacrum and coccyx, which was often exacerbated by prolonged sitting. How-

ever, few of these patients exhibited tenderness of the coccyx on direct palpation or manipulation. Common aetiological factors included anal infection and chronic trauma, as identified in 178 (55%) and 106 (33%) patients, respectively.

Lubkan & Whitmore (2002) described Thiele massage performed transvaginally as being more comfortable for patients. In performing this technique, pressure was applied longitudinally from the origin to the insertion of the pelvic floor muscle (PFM) fibres. Ten to 15 sweeps of maximally tolerated pressure were applied on each side, followed by myofascial massage (10–15 s of sustained pressure) to tender points. Patients were treated once or twice a week for 6–8 weeks, which was less frequent than Thiele prescribed. Lubkan & Whitmore (2002) stated that Thiele applied his initial course of therapy every day for 5–6 days, and then every other day for 7–10 days.

Paradis & Marganoff (1969) used the term “coccygeus-levator spasm syndrome” to characterize 92 patients with pelvic floor spasm and

Correspondence: Maeve Whelan MSc SMISCP DipObsGyn (Physio), Specialist Chartered Physiotherapist, Milltown Physiotherapy Clinic, 98 Lower Churchtown Road, Dublin 14, Ireland (e-mail: maevewhelan@me.com).

“rectal” pain in an article on rectal pain of extrarectal origin. Patients were found to be particularly tender at muscular sites adjacent to the ischial spines and coccyx. Neither infection nor trauma was identified as an aetiological factor in these subjects. Grant *et al.* (1975) used the term “levator syndrome” to describe a sample of 316 patients exhibiting PFM spasm and tenderness. The predominant symptom was rectal discomfort. The aetiology of levator syndrome was reported as unknown. Malbohan *et al.* (1989) described the role of coccygeal spasm in low back pain.

Current guidelines

The importance of musculoskeletal evaluation in pelvic floor dysfunction has recently become more generally recognized. In the European Association of Urology (EAU) guidelines on chronic pelvic pain (CPP), Fall *et al.* (2010, p. 39) defined PFM pain syndrome as: “Persistent or recurrent episodic pelvic floor pain with associated trigger points [TrPs] either related to the micturition cycle or associated with symptoms suggestive of urinary tract, bowel, or sexual dysfunction.” Therefore, where there were once only a few individuals who saw the need to assess the musculoskeletal system, there is now more agreement that this kind of evaluation is important in many urogynaecological and colorectal conditions, and it is recommended that the PFMs are palpated as a first-line treatment in all cases when evaluating CPP (Fall *et al.* 2010).

The updated EAU CPP guidelines (Engeler *et al.* 2012) state that the musculoskeletal system must be evaluated in the same way as the urological, gynaecological, gastrointestinal, peripheral nervous, sexological and psychological systems. Furthermore, the PFMs, abdominal muscles and spine should be examined as end-organs of pain. The American Urological Association states that appropriate manual physical therapy techniques (e.g. manoeuvres that resolve pelvic, abdominal and/or hip muscular TrPs, lengthen muscle contractures, and release painful scars and other connective tissue restrictions) should be offered as a second-line treatment if suitably trained clinicians are available, and that pelvic floor strengthening exercises (e.g. Kegel exercises) should be avoided (Hanno *et al.* 2011).

Palpation and manual therapy in the literature

Kavvadias *et al.* (2011) reviewed 69 articles on pain in urogynaecology. The sites of pain were

specified in 31 papers (45%), nine (13%) mentioned bladder pain, nine (13%) referred to musculoskeletal pain (e.g. of the levator ani, pubo- and iliococcygeus, piriformis, ischiococcygeus, and obturator internus muscles), and 14 papers (20%) referred to other sites of pain, such as vaginal, vulvar, urethral or low back pain, or pain in the lower abdomen. One study specified the type of bladder pain described as bladder neck pain by using vaginal examination. In the remaining 37 articles (54%), the location of the pain was not specified. Vaginal examination was performed in 14 studies (20%). In 13 of the articles (19%), the diagnosis was of CPP.

Table 1 gives outlines of some of the more relevant papers reviewed by Kavvadias *et al.* (2011), includes more recent studies, and examines the difficulties associated with and differences between various palpation techniques. It can be seen from these studies that painful levator ani, obturator internus, ischiococcygeus and piriformis muscles are prevalent in symptomatic female and male patients.

There has been little research on the reliability of palpation methods, and in what literature there is, the reports of reliability have been very varied. Table 2 outlines these studies.

Table 3 lists the studies of manual therapy that have been published to date. The various techniques used and the range of intervention dosages are described.

Loving *et al.* (2012) published a systematic review entitled “Does evidence support physiotherapy management of adult female chronic pelvic pain? A systematic review”. They concluded that there was insufficient evidence to allow conclusions to be drawn about the effects of psychosomatic group treatment and modified Thiele massage, even though studies of these interventions have demonstrated a statistically significant pre–post reduction in pain using visual analogue scales.

The nature of trigger points

In a literature review, Lucas *et al.* (2009) described TrPs as hyperirritable nodules located within taut bands of skeletal muscle that are tender when palpated and produce referred pain. After a TrP is identified, clinicians determine whether it is “active” (i.e. symptomatic) or “latent” (i.e. asymptomatic). The criterion that the patient’s pain can be reproduced by palpation of the tender point within the taut band is essential for the diagnosis of an active TrP.

Table 1. Palpation for pain and tone in urogynaecology studies: (CPP) chronic pelvic pain; (IC) interstitial cystitis; (SF-MPQ) Short-Form McGill Pain Questionnaire; (VAS) visual analogue scale; (MOS) Modified Oxford Scale; (ADLs) activities of daily living; (PUF) Pelvic Pain and Urgency/Frequency; (R) right; (L) left; (TrP) trigger point; (PFDI-20) Pelvic Floor Distress Inventory; and (PFIQ-7) Pelvic Floor Impact Questionnaire

Reference	Design and participants	Measurements	Outcomes
Tu <i>et al.</i> (2007)	Prospective, comparative, observational study ($n=16$ women with CPP, $n=30$ controls)	Algoter for instantaneous measurement of the pressure-pain detection threshold (kg/cm^2); pubococcygeus measured at 2 and 10 o'clock, iliococcygeus and ischiococcygeus at 5 and 7 o'clock, obturator internus at 3 and 9 o'clock, anterior vaginal site at 12 o'clock, and posterior vaginal site measured at 6 o'clock; right index finger inserted 5 cm proximal to the introitus for all measurements; ischiococcygeus measured at the same clock face orientation as iliococcygeus, but at 10 cm proximal SF-MPQ	Significantly lower pressure-pain detection threshold values at all eight sites among women with CPP Right- and left-sided pelvic floor measurements negatively correlated with SF-MPQ sensory subscores ($r = -0.57$, $P=0.03$; $r = -0.67$, $P=0.009$), similar to posterior vaginal wall pressure-pain detection threshold ($r = -0.55$, $P=0.04$) No scores correlated with pressure-pain detection threshold at any site
Peters <i>et al.</i> (2007)	Prevalence ($n=70$ women with IC and CPP; mean age=45 years)	Assessed for levator pain during a vaginal examination: pressure was applied laterally on the levator muscles on the right and left at the ischial spines for consistency in locating and evaluating pain levels on a VAS as an appropriate point to assess levator tension with identifiable landmarks, and anteriorly, underneath the pubic rami	The vast majority of the sample had levator pain (87%) and dyspareunia (71%) The average levator pain score was 4.48 out of 10 Interestingly, the average score on the left side was greater than that on the right (4.75 versus 4.2 out of 10)
Dietz & Shek (2008)	Prospective study to test a newly developed resting tone scale for validity and reproducibility ($n=98$)	Six-, 11- and 21-point resting scales Palpation was performed using one finger on the medial aspect of the puborectalis muscle, just anterior to the anorectal junction, at about 4-5 o'clock: (0) muscle not palpable; (1) muscle palpable, but very flaccid, wide hiatus, minimal resistance to distension; (2) hiatus wide, but some resistance to distension; (3) hiatus fairly narrow, fair resistance to palpation, but easily distended; (4) hiatus narrow, muscle can be distended, but high resistance to distension, no pain; and (5) hiatus very narrow, no distension possible, "woody" feel, possibly with pain, i.e. "vaginismus"	The MOS scores and resting tone were determined separately for the right and left puborectalis; the mean MOS score was 2.6 and the mean resting tone was 2.8 Reduced resting tone was associated with cystocele for the six- ($P=0.019$) and 21-point scales ($P=0.04$) For posterior compartment descent, $P=0.046$, 0.048 and 0.032 for the six-, 11- and 21-point scales, respectively None of the MOS scores was significantly associated with clinical prolapse grading Resting tone showed significant associations with levator hiatal dimensions (the 11-point scale performed best) No major differences in discriminatory ability when comparing the six-, 11-, and 21-point scales against each other
Tu <i>et al.</i> (2008)	Prospective cross-sectional study ($n=19$ women with CPP for at least 3 months, $n=20$ healthy control subjects; age range=18-55 years)	Pelvic pain was self-scored from 0 to 3: (0) none; (1) pain that does not interfere with ADLs; (2) pain that interferes with ADLs; and (3) pain that prevents the performance of ADLs Pubococcygeus, iliococcygeus, ischiococcygeus and obturator internus muscles each palpated bilaterally with gentle turning motions of the examiner's index finger; pain reaction scored by observation: (0) no pain; (1) verbal report of pain; (2) verbal report and grimace; and (3) grimace plus attempt to withdraw (maximum score of three times eight sites =24) PUF patient symptom scale completed	Patients with CPP had more frequent abnormal musculoskeletal findings: asymmetric iliac crests (61% versus 25%; $P<0.05$); pubic symphysis heights (50% versus 10%; $P<0.05$); and positive pelvic pain provocation testing (37% versus 5%; $P<0.05$) Higher median total pelvic floor tenderness scores (3/24 versus 0/24; $P<0.05$) Less control of the pelvic floor (unable to relax pelvic floor for 10 s (78% versus 20%; $P<0.001$) PUF score: 0-20; (median) 11 versus 5 ($P<0.05$) Reliability: obturator internus (R), iliococcygeus (R) and ischiococcygeus (L) muscle examinations showed moderate to fair agreement ($\kappa=0.44-0.63$)

Continued

Table 1. (Continued)

Reference	Design and participants	Measurements	Outcomes
Anderson <i>et al.</i> (2009)	Case series ($n=72$ men with a diagnosis of CPP syndrome)	Penis, perineum, rectum, suprapubic region, testes, groin and coccyx/buttocks palpated to identify TrPs; no myofascial tissue release; semilateral prone position; pressure applied for tissue palpation with force of 4 kg/cm ² Patients reported their level of pain during palpation: (0) none; and (≥ 3) severe Only pain reported as ≥ 2 or ≥ 3 was counted as "yes, pain is present", while a score of 0 or ≥ 1 was counted as no pain	Five of the seven painful sites could be reproduced at least 50% of the time ($P<0.05$) The most prevalent pain sites were: the penis (90.3%); the perineum (77.8%); and the rectum (70.8%) Puborectalis/pubococcygeus and rectus abdominis TrPs reproduced penile pain more than 75% of the time ($P<0.01$); external oblique muscle palpation elicited suprapubic, testicular and groin pain in at least 80% of patients at the respective pain sites ($P<0.01$)
Carrico & Peters (2011)	Clinical trial ($n=21$ women, before and after 1 month of diazepam)	Pressing the index finger laterally during vaginal examination to assess levator muscles for spasm or TrPs measured on a 10-point VAS	Some 62% markedly or moderately improved Overall mean pain decreased from 4.8 to 3.4/10 Average levator pain (R and L combined) decreased from 3.8 before diazepam to 1.8 afterwards
Bassaly <i>et al.</i> (2011)	Retrospective chart review ($n=186$ patients with a diagnosis of IC; age range=18–78 years)	Obturator internus, arcus tendineus, iliococcygeus, puborectalis and rectus abdominis muscles were bilaterally palpated for myofascial pain Patients verbally scored each muscle for pain on a 10-point scale: (0) no pain; and (10) worst pain ever experienced An effort was made to be consistent in the pressure applied in the manner of a normal gynaecological examination	Myofascial pain in 78.5% of patients with IC, classified by at least one pelvic floor and/or rectus abdominis TrP during myofascial examination Of the patients with IC, 67.9% had six or more TrPs: obturator internus (L), 72%; puborectalis (R), 74%; obturator internus (R), 68.8%; puborectalis (L), 68.8%; arcus tendineus (L), 68.3%; and iliococcygeus (L), 67.2% Only mild correlations were noted between myofascial TrPs and validated questionnaires (i.e. the PUF, PFDI-20 and PFIQ-7), none greater than 0.3

Table 2. Reliability of palpation: (R) right; (L) left; and (ICC) intra-class correlation coefficient

Reference	Location	Pressure	Score	Reliability
Tu <i>et al.</i> (2008)	Obturator internus (R), iliococcygeus (R) and ischiococcygeus (bilateral) muscle examinations	Small rotating movements of the index finger	Four-point scale, eight sites (total score = 0/24)	Moderate to fair agreement on a collapsed two-point scale ($\kappa=0.44-0.63$)
Slieker-ten Hove <i>et al.</i> (2009)	Anterior and posterior vaginal walls (bilateral)	One finger, amount of pressure not stated	Dichotomous pain scale, i.e. present or absent	Intra-rater reliability = 0.79; inter-rater reliability = 0.85
Montenegro <i>et al.</i> (2010b)	Levator ani, piriformis and obturator internus muscles (bilateral)	One finger, in as comfortable and delicate a manner as possible	Scale: (0) no pain; (1) painful discomfort; and (2) intense pain (maximum score = 12)	For tenderness of the pelvic muscles, $\kappa=0.91$ (levator ani not differentiated)
Kavvadias <i>et al.</i> (2013)	Anterior and posterior levator ani, obturator internus, and piriformis muscles	Pressure was steadily applied	Eleven-point pain scale from 0 to 10 (clinically significant pain ≥ 3)	Inter-rater reliability varied (ICC = 0.28–0.87) for the levator ani (better for the obturator internus and piriformis)

There are only limited data on the reliability of pinpointing the exact location of active TrPs, and according to Lucas *et al.* (2009), physical examination cannot currently be recommended as a reliable test for the diagnosis of TrPs. Since their paper was a review on the literature on TrPs in the musculoskeletal system in general, this would certainly be the case with regard to the PFMs because of the greater limitation of access to these muscles. Furthermore, there tends to be reluctance on the part of any therapist to exert sufficient pressure to elicit a TrP local twitch response.

Trigger points are thought to develop following unaccustomed eccentric and concentric loading in particular, but these also occur after low-load repetitive tasks and sustained postures, and in association with visceral pain and dysfunction. The taut band formation may reflect a normal protective and stabilizing physiological mechanism; for example, TrPs might be associated with damage or potential muscle damage, joint hypermobility, visceral dysfunction, or abnormal breathing patterns. Prolonged contractures are likely to lead to the formation of latent TrPs, which can evolve into active ones (Dommerholt 2011). This mechanism is described apropos of all muscles and can be more specifically applied to the PFMs.

The concept of taut bands and load in pelvic organ prolapse

There is a certain amount of agreement in the literature with regard to the mechanism of loading to the pelvic floor as a result of fascial and muscular damage. A study of 160 women by DeLancey *et al.* (2003) showed the appearance of levator muscle injury using magnetic resonance imaging (MRI). These authors stated that damage to the PFMs results in sagging and tipping of the levator plate, and that decreased muscular support presumably increases the load on the fascia and connective tissue of the pelvis. They further suggested that, because the load carried by the pelvic floor is shared between the muscles and the connective tissues, a decrease in muscle function would shift an additional load to the fibrous elements. DeLancey *et al.* (2003) found muscle injuries in 32 women, and of that total, the iliococcygeus muscle was injured in only 10% of cases ($n=3$), while the pubovisceralis muscle was injured in the remaining 90% ($n=29$).

In a study of the position of the levator plate using MRI, Hsu *et al.* (2006) considered an

Table 3. Manual therapy studies: (TrP) trigger point; (PFM) pelvic floor muscle; (CPP) chronic pelvic pain; (PBS) painful bladder syndrome; (IC) interstitial cystitis; (MOS) Modified Oxford Scale; (ICSI) Interstitial Cystitis Symptom Index; (SPI) Symptom Problem Index; (VAS) visual analogue scale; (SF-12) Short Form Health Survey; (QoL) quality of life; (PFSS) Pelvic Pain Symptom Survey; (NIH-CPSI) National Institutes of Health Chronic Prostatitis Symptom Index; (GRA) Global Response Assessment; and (MPI) McGill Pain Index

Reference	Design and participants	Evaluation	Intervention	Results
Holzberg <i>et al.</i> (2001)	Pilot study ($n=10$ subjects with a confirmed diagnosis of IC)	Genitourinary physical exam to elicit and document pelvic floor tone and TrPs, as well as an objective evaluation of resting and contracting pressures during a Kegel manoeuvre	Six intravaginal massage sessions using the Thiele "stripping technique": deep vaginal massage via a back-and-forth motion over the levator ani, obturator internus and piriformis muscles, as well as a myofascial release technique; when a TrP was identified, pressure was held for 8–12 s and then released	Some 90% of patients showed a subjective improvement in frequency and/or nocturia, urgency and pain. The digital exam showed a marked improvement in the patients' ability to contract and then relax their pelvic floor musculature
Weiss (2001)	Case series ($n=10$ subjects with IC, $n=42$ subjects with urgency frequency syndrome; women=45, men=7)	Transvaginal or transrectal approach (urinary and anal sphincter, pubourethralis, pubovaginalis, puborectalis, iliococcygeus, obturator internus, and piriformis), to identify tightness, tenderness, taut bands and pain radiation depicting symptoms. Connective tissue lateral to the urethra (women), and puboprostatic muscle lateral to the prostate and urogenital diaphragm (men). Subjective pain rating: (0) none; and (4) severe	One or two sessions per week for 8–12 weeks of PFM compression, stretching and strumming, external muscle stretching, or heat application. Transvaginal or transrectal posterior traction with an isometric contraction of the pubovaginalis muscle to relax and elongate. Intramuscular injections (1–2 mL of 0.5% bupivacaine/1% lidocaine) to any discrete TrPs remaining after 6–8 weeks of therapy	Seven subjects (70%) with IC showed a moderate (51–75%) to marked (76–99%) improvement, as determined by patient-completed score sheets. Of the 42 subjects with urgency-frequency, 35 (83%) showed a moderate to marked improvement. Ten patients improved electromyographic resting pelvic floor tension: mean decrease from 9.73 to 3.6 μ V (65%). No statistical analysis.
Oyama <i>et al.</i> (2004)	Prospective clinical pilot study ($n=21$ symptomatic female patients with IC and high-tone dysfunction of the pelvic floor)	Initial vaginal examination to document PFM tenderness of the ischiococcygeus, iliococcygeus, pubococcygeus and obturator internus. Five-point MOS: (0) no pressure or pain; (1) comfortable pressure; (2) uncomfortable pressure; (3) moderate pain, intensified with muscle contraction; and (4) severe pain, patient unable to perform muscle contraction because of pain	Ten intravaginal sessions using the Thiele technique by one of three women's health nurse practitioners; massage from origin to insertion along the direction of the muscle fibres with an amount of pressure tolerable to the subject; motion performed 10–15 times during each session for each of the muscles in order (i.e. ischiococcygeus, iliococcygeus, pubococcygeus and obturator internus); 10–15 s of ischaemic compression to TrPs for 5 min (at least 2 days apart); two massages per week for 5 weeks. Symptoms were evaluated before and after massages, and at a mean of 4.5 months after completion of therapy	O'Leary–Sant ICSI, SPI and Likert–VAS for urgency and pain, and SF-12 for QoL. The SPI ($P=0.015$), ICSI ($P=0.039$) and VAS for urgency ($P=0.001$) and pain ($P=0.005$) all improved, as did the SF-12 QoL scales ($P=0.049$ and 0.044). The MOS improved ($P<0.05$) after completion of the protocol. At long-term follow-up, the ICSI and SPI ($P=0.049$ and 0.02 , respectively) remained improved, as did the VAS ($P=0.004$ and 0.005) and MOS for three of the four PFM's ($P<0.05$), but not the ischiococcygeus.

Continued

Table 3. (Continued)

Reference	Design and participants	Evaluation	Intervention	Results
Anderson <i>et al.</i> (2006)	Sexual dysfunction study ($n=146$ men with chronic pelvic pain syndrome for at least 1 month; mean age=42 years)	Pelvic muscles examined to identify TrPs producing pain at the site or referring it The PPSS and NIH-CPSI were used to document the severity/frequency of pain, and urinary and sexual symptoms, and the GRA to record patient perceptions of overall therapeutic effects at an average follow-up of 5 months	Physiotherapist applied treatment with the patient in the prone and lateral positions, palpating individual muscle groups and releasing TrPs with applied pressure weekly for 4 weeks, and then biweekly for 8 weeks thereafter Patients were also given paradoxical relaxation training to decrease and modify PFM holding patterns Patients participated in a 6-day, 30-h intensive treatment initiation phase	The GRA scores ($n=103$, 70%) markedly or moderately improved ($P<0.001$) The PPSS total pain and urinary scores markedly or moderately improved ($P<0.001$) Sexual function scores decreased by 43% in men who showed a marked improvement ($P<0.001$), but only by 10% in those exhibiting only a moderate improvement The NIH-CPSI total scores decreased by 9.2 (35%) and 7 points (26%) for those who markedly or moderately improved, respectively
FitzGerald <i>et al.</i> (2009)	Randomized controlled trial ($n=48$ men and women with CPP, PBS or prostatitis; $n=23$ received myofascial physical therapy, $n=24$ formed the control group, who received global therapeutic massage)	An additional eligibility requirement was the finding of pelvic floor tenderness during vaginal examination by the study's physician, as confirmed by the study's physical therapist	The treatment group received myofascial therapy in the form of connective tissue manipulation, i.e. rolling the connective tissue layer over the thighs, buttocks and entire pelvic floor area	The primary outcome measure was the GRA scale: there was a higher GRA rate of 57% in the myofascial physical therapy group, as compared to 21% in the global massage group ($P=0.03$) Physician's baseline examination of right- and left-sided pelvic floor tenderness before (17.78) and after treatment (10.96) on a scale of 0–6 per muscle group across four PFM groups ($P<0.001$)
Montenegro <i>et al.</i> (2010a)	Case series ($n=6$)	Vaginal palpation with one finger in order to identify tenderness of the levator ani muscle bilaterally: (0) no pain; (1) painful discomfort; and (2) intense pain (total score=2)	“Thiele's” vaginal massage from origin to insertion along the direction of the muscle fibres using an amount of pressure tolerable to the subject over a period of 5 min once per week for 4 weeks; re-evaluate after 1 month	Reduction in tenderness scores from 3 to 0 ($P<0.01$) Reduction in VAS scores from 8.1 to 1.5 ($P<0.01$) Reduction in MPI scores from 34 to 16.6 ($P<0.01$)

Continued

Table 3. (Continued)

Reference	Design and participants	Evaluation	Intervention	Results
Anderson <i>et al.</i> (2011)	Case series ($n=200$ men prescribed a treatment protocol for CPP syndrome, $n=116$ were followed for a median of 6 months)	Repeat methodical manual external and rectal muscle examination performed by a physical therapist to document active myofascial TrPs Patients reported their subjective sensations of pelvic pain in the penis, perineum, rectum, suprapubic region, testes, groin and coccyx/buttocks, and any sites of referred pain after manipulation of a TrP	For 5 days consecutively, the same physical therapist performed myofascial TrP release and trained patients in self-administration of the method: semilateral, prone position with pillows under the abdomen; the internal posterior and anterior pelvic muscles of the sphincter ani were examined, turning the patient as necessary; a traditional palpation force of approximately 4 kg/cm ² was used for tender points	Outcome measures included the VAS and NIH-CPSI The baseline score was 26 out of a maximum of 43 points Scores decreased by 30% ($P<0.001$) at follow-up, with 60% demonstrating a 6-point or greater reduction The pain, urinary dysfunction and QoL domains showed significant improvements ($P<0.001$) The GRA scores revealed that 82% of subjects reported an improvement (59% marked to moderate, 23% slight)
FitzGerald <i>et al.</i> (2012)	Randomized controlled trial ($n=81$ women with IC/PBS; $n=39$ received myofascial physical therapy, $n=42$ formed the control group, who received global therapeutic massage)	An additional eligibility requirement was the finding of pelvic floor tenderness during a vaginal examination by the study's physician, as confirmed by the study's physical therapist	Subjects received a trial of 10 scheduled treatments of targeted internal and external tissue manipulation, focusing on the muscles and connective tissues of the pelvic floor, hip girdle and abdomen	The primary outcome measure was the GRA score Secondary outcome measures included ratings for pain, urgency and frequency, ICIS and SPI scores, and reports of adverse events The GRA was 26% in the therapeutic massage group and 59% in the myofascial physical therapy group ($P=0.012$) Pain, urgency and frequency ratings, and ICIS and SPI scores decreased in both groups during follow up, and were not significantly different between the groups

increase in levator plate angle (LPA) to be an indicator of damage to the levator muscle. They suggested that the bigger load on the iliococcygeus as a result of pubovisceralis damage could be a mechanism for the downward displacement of the LPA.

DeLancey *et al.* (2012) stated that pelvic organ prolapse (POP) is associated with a tear of greater than 50% and described the “compensatory hypertrophy hypothesis”, i.e. where the ventral portion of the levator ani is damaged, the intact dorsal portion hypertrophies in compensation. They proposed that this may explain why a loss of less than 50% of the muscle is not associated with prolapse, but a loss of greater than 50% has a significant association with POP. In lesser degrees of injury, the remaining muscle can hypertrophy in order to take over some of the lost function, while greater degrees of injury exceed the capability of the remaining muscle to increase its activity. In accordance with the above study, Hsu *et al.* (2008) also found thicker levator ani musculature dorsally and a more prominent puborectal muscle on MRI.

Dietz (2009) described palpation associated with bilateral avulsion of the levator ani, noting marked hypertrophy of the pubococcygeus/iliococcygeus, resulting in a levator shelf that is almost as “strong” as the original, just somewhat higher and wider. He stated that avulsion often seems to have an impact on adjacent or contralateral intact muscles. Dietz (2009) also noted that the intact contralateral puborectalis may become spastic and very tender after unilateral avulsion. Where this is described as “strong”, it might be interpreted as “loaded” in physiotherapy terms, but perhaps these words mean the same thing.

Physiotherapists can manually identify variability in hypertrophied and “loaded” muscle in PFM rehabilitation, although their skills and ability will vary, as will the reliability of their measurements (Sliker-ten Hove *et al.* 2009). Clinically, however, a physiotherapist can palpate a tear in the levator muscle and identify when there is a hypertrophied muscle. A hypertrophied puborectalis can often be found beside a more “loaded” iliococcygeus when there has been damage to the PFMs and fascia. In physiotherapy terms, “load” might be palpated as a fibrous, hard, almost tendinous end-feel of tension under the palpating finger. This type of end-feel is distinct from the high-tone pelvic floor or short pelvic floor, as described by Fitzgerald & Kotarinos (2003), which may also

be hard on palpation, but has a more springy resistance. These terms have been explored by past international standardization committees, and this work is currently ongoing (Messelink *et al.* 2005; Haylen *et al.* 2010).

Manual therapy techniques

Simons *et al.* (1999) described the basis of the three manual therapy techniques that can be applied to the pelvic floor, i.e. flat, deep and pincer palpation. In flat palpation, the therapist’s fingertip slides the overlying fascia aside and palpates across the fibres that are to be examined. In deep palpation, the intervening tissue overlies the muscle containing the taut bands or TrPs, and palpation through this tissue is necessary; this technique is more suitable for the deeper levator ani muscles. In pincer palpation, the muscle is grasped between the fingertip and thumb to press or roll the fibres forwards and backwards in order to locate taut bands; this technique is used for the more accessible tissue. These approaches are applied and modified depending on the anatomy of the pelvic floor that is to be treated.

The superficial PFMs should be treated with flat palpation techniques, whereas the deep PFMs would need to be accessed with those of deep palpation. The attachments of the levator ani can be treated using either flat or pincer palpation, as can the perineal body. The deep PFMs can also be treated using pincer palpation internally to externally in those patients where size makes this anatomically possible. The external anal sphincter can also be treated vaginally using pincer palpation. All of the techniques that are practised vaginally can be performed rectally, depending on levels of comfort and access. Supine, side-lying and prone positions are all potential options. Rolling the tissue and medial to lateral movement, or cephalad-to-caudad or caudad-to-cephalad movement, can be performed where possible in order to mobilize the tissue.

External connective tissue manipulation techniques are invaluable methods of releasing restricted perineal tissue in the distribution of all branches of the pudendal nerve (i.e. the inferior rectal, perineal and dorsal clitoral nerves), and are also beneficial in the distribution of the posterior femoral cutaneous nerve. These techniques can have a marked effect on the behaviour of the internal PFMs. In many cases of pelvic floor dysfunction, it is good practice to

assess internally, then treat tissue externally, and subsequently, reassess internally to determine the effect of these external restrictions on the behaviour of the PFMs internally.

The direction of release is important in internal manual therapy to the levator ani, and therefore, deep pressure into the muscle may work best rather than repetitive massage techniques (e.g. strumming or stripping) where these methods of palpation might also be quite irritating for the vaginal tissue. While uncomfortable on the taut bands or TrPs treated, these techniques as described should never be uncomfortable on the vaginal tissue being accessed. The iliococcygeus muscle is attached to the coccyx and the ischial spine posteriorly, and therefore, the tendency is for the muscles to be held back. It is for this reason that manual therapy is directed posteriorly in the first instance so as to release/facilitate posterior attachments, and then towards the anterior attachments to the pubic bone so that release techniques are based on the direction of the muscle fibre and the sensitivity of the vaginal tissue.

The abdomen plays a role in pelvic floor dysfunction and manipulation is effective in the abdominal connective tissue. Superficial and deep taut bands and TrPs can also be treated with palpation techniques in the abdomen.

Dry needling is an adjunct to treatment, and it may be the therapy of choice when muscles/fascia are not releasing easily. This approach may also be used for PFMs, and it could be that needling techniques are more “comfortable” than other forms of manual therapy and may be the treatment of choice in such cases.

One of the significant findings and indicators of success or otherwise in patients with POP is whether, when their muscles have been treated and have become more mobile, these remain flexible or constantly re-inhibit. It can be noted in individuals who do not improve that their muscles either do not change as easily, or if these do adjust, then these can regress or re-inhibit more easily. One of the measures of this, although it is not reliable, is to estimate how well an individual releases after a pelvic floor contraction. For example, if the patient contracted to Modified Oxford Scale (MOS) Stage 4 (Laycock *et al.* 2008), then the release could be calculated as a percentage of that contraction, i.e. a MOS Stage 4 contraction with 70% release means that, although the muscle is quite strong, there is still some tension in it that needs to be released. Once the end-feel changes, the cranio-ventral lift of the pelvic floor increases, and there

is an improved excursion in the muscle as a result of greater mobility. Therefore, not only are the grade of the lift and the quality of the release evaluated, but also the excursion of the muscle group.

Single case study

The present author applied these techniques in a single case study, and found a change of 8° in

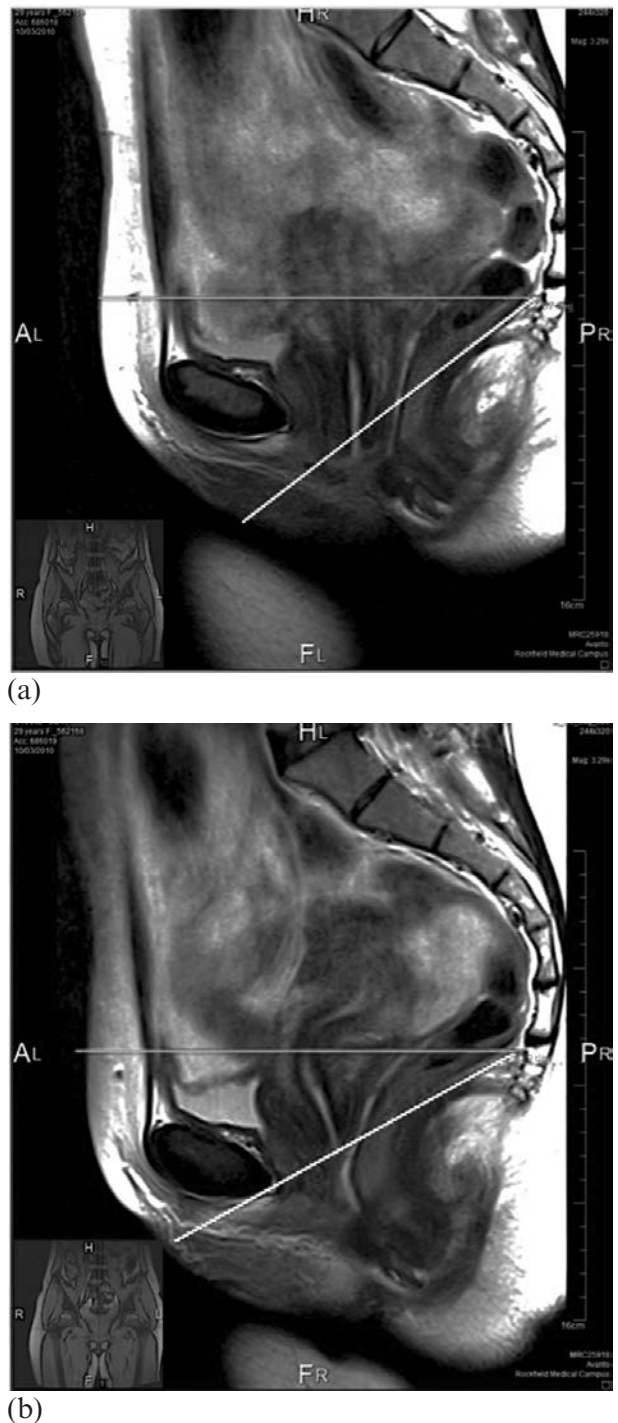


Figure 1. Magnetic resonance imaging scans showing the angle of the levator plate (a) before (37°) and (b) after (29°) manual therapy. Note the elevated position of the uterus following treatment.

the LPA before and after a single, 30-min session of manual therapy. The 30-year-old subject had presented with stage II prolapse of the uterus.

Therapy consisted of deep pressure that was direction-specific to the taut bands of the levator plate and the posterior levator ani. Other treatment within the session was intended to facilitate an improved contract-relax technique, and to improve the depth of the relaxation component through use of the “sniff, flop and drop” approach (Whelan 2012). Before and after MRI scans of the subject’s LPA are shown in Figure 1.

The present author then recruited 12 subjects in order to do an extended version of this study using MRI scans of the position of the levator plate as an outcome measure, as well as the POP quantification system and a subjective questionnaire. The results of this study have not yet been published.

Conclusion

Manual therapy for pelvic floor dysfunction has developed over the past 75 years, and it is only recently that it has been fully recognized by the medical profession as a key part of a urogynaecological or pelvic evaluation. As a therapy, it forms only part of the full musculoskeletal picture, and management must always be multidisciplinary. However, as referrals from colleagues increase and recognition grows, it has become increasingly important that a physiotherapist’s skill in palpation, evaluation and treatment is well developed. Manual therapy is not just limited to musculoskeletal pain, urological pain and CPP, but can extend to all urogynaecological disorders. As ever, more large-scale research studies are needed to evaluate the effect that musculoskeletal physiotherapy can have on all urogynaecological disorders in the promotion of conservative care.

References

- Anderson R. U., Sawyer T., Wise D., Morey A. & Nathanson B. H. (2009) Painful myofascial trigger points and pain sites in men with chronic prostatitis/chronic pelvic pain syndrome. *The Journal of Urology* **182** (6), 2753–2758.
- Anderson R. U., Wise D., Sawyer T. & Chan C. A. (2006) Sexual dysfunction in men with chronic prostatitis/chronic pelvic pain syndrome: improvement after trigger point release and paradoxical relaxation training. *The Journal of Urology* **176** (4), 1534–1539.
- Anderson R. U., Wise D., Sawyer T., Glowe P. & Orenberg E. K. (2011) 6-day intensive treatment protocol for refractory chronic prostatitis/chronic pelvic pain syndrome using myofascial release and paradoxical relaxation training. *The Journal of Urology* **185** (4), 1294–1299.
- Bassaly R., Tidwell N., Bertolino S., *et al.* (2011) Myofascial pain and pelvic floor dysfunction in patients with interstitial cystitis. *International Urogynecology Journal* **22** (4), 413–418.
- Carrico D. J. & Peters K. M. (2011) Vaginal diazepam use with urogenital pain/pelvic floor dysfunction: serum diazepam levels and efficacy data. *Urologic Nursing* **31** (5), 279–284, 299.
- DeLancey J. O. L., Kearney R., Chou Q., Speights S. & Binno S. (2003) The appearance of levator ani muscle abnormalities in magnetic resonance images after vaginal delivery. *Obstetrics and Gynecology* **101** (1), 46–53.
- DeLancey J. O. L., Sørensen H. C., Lewicky-Gaup C. & Smith T. M. (2012) Comparison of the puborectal muscle on MRI in women with POP and levator ani defects with those with normal support and no defect. *International Urogynecology Journal* **23** (1), 73–77.
- Dietz H. P. (2009) Pelvic floor assessment. *Fetal and Maternal Medicine Review* **20** (1), 49–66.
- Dietz H. P. & Shek K. L. (2008) The quantification of levator muscle resting tone by digital assessment. *International Urogynecology Journal and Pelvic Floor Dysfunction* **19** (11), 1489–1493.
- Dommerholt J. (2011) Dry needling – peripheral and central considerations. *The Journal of Manual and Manipulative Therapy* **19** (4), 223–227.
- Engeler D., Baranowski A. P., Elneil S., *et al.* (2012) *Guidelines on Chronic Pelvic Pain*. [WWW document.] URL http://www.uroweb.org/gls/pdf/24_Chronic_Pelvic_Pain_LR%20March%202023th.pdf
- Fall M., Baranowski A. P., Elneil S., *et al.* (2010) EAU guidelines on chronic pelvic pain. *European Urology* **57** (1), 35–48.
- FitzGerald M. P., Anderson R. U., Potts J. *et al.* (2009) Randomised multicenter feasibility trial of myofascial physical therapy for the treatment of urological chronic pelvic pain syndromes. *The Journal of Urology* **182** (2), 570–580.
- FitzGerald M. P., Payne C. K., Lukacz E. S. *et al.* (2012) Randomised multicenter clinical trial of myofascial physical therapy in women with interstitial cystitis/painful bladder syndrome and pelvic floor tenderness. *The Journal of Urology* **187** (6), 2113–2118.
- FitzGerald M. P. & Kotarinos R. (2003) Rehabilitation of the short pelvic floor. I: Background and patient evaluation. *International Urogynecology Journal* **14** (4), 261–268.
- Grant S. R., Salvati E. P. & Rubin R. J. (1975) Levator syndrome: an analysis of 316 cases. *Diseases of the Colon and Rectum* **18** (2), 161–163.
- Hanno P. M., Burks D. A., Clemens J. Q., *et al.* (2011) *Diagnosis and Treatment of Interstitial Cystitis/Bladder Pain Syndrome*. [WWW document.] URL <http://www.auanet.org/common/pdf/education/clinical-guidance/IC-Bladder-Pain-Syndrome.pdf>
- Haylen B. T., de Ridder D., Freeman R. M., *et al.* (2010). An International Urogynecological Association (IUGA)/International Continence Society (ICS) joint report on the terminology for female pelvic floor dysfunction. *International Urogynecology Journal* **21** (1), 5–26.

- Holzberg A., Kellog-Spadt S., Lukban J. & Whitmore K. (2001) Evaluation of transvaginal Thiele massage as a therapeutic intervention for women with interstitial cystitis. [Abstract.] *Urology* **57** (Suppl. 6A), 120.
- Hsu Y., Lewicky-Gaupp C. & DeLancey J. O. L. (2008) Posterior compartment anatomy as seen in magnetic resonance imaging and 3-dimensional reconstruction from asymptomatic nulliparas. *American Journal of Obstetrics and Gynecology* **198** (6), 651.e1–651.e7.
- Hsu Y., Summers A., Hussain H. K., Guire K. E. & DeLancey J. O. L. (2006) Levator plate angle in women with pelvic organ prolapse compared to women with normal support using dynamic MR imaging. *American Journal of Obstetrics and Gynecology* **194** (5), 1427–1433.
- Kavvadias T., Baessler K. & Schuessler B. (2011) Pelvic pain in urogynaecology. Part I: Evaluation, definitions and diagnoses. *International Urogynecology Journal* **22** (4), 385–393.
- Kavvadias T., Pelikan S., Roth P., Baessler K. & Schuessler B. (2013) Pelvic floor muscle tenderness in asymptomatic, nulliparous women: topographical distribution and reliability of a visual analogue scale. *International Urogynecology Journal* **24** (2), 281–286.
- Laycock J., Whelan M. M. & Dumoulin C. (2008) Patient assessment. In: *Therapeutic Management of Incontinence and Pelvic Pain: Pelvic Organ Disorders*, 2nd edn (eds J. Laycock & J. Haslam), pp. 57–66. Springer, London.
- Loving S., Nordling J., Jaszczak P. & Thomsen T. (2012) Does evidence support physiotherapy management of adult female chronic pelvic pain? A systematic review. *Scandinavian Journal of Pain* **3** (2), 70–81.
- Lubkan J. C. & Whitmore K. E. (2002) Pelvic floor muscle re-education treatment of the overactive bladder and painful bladder syndrome. *Clinical Obstetrics and Gynecology* **45** (1), 273–285.
- Lucas N., Macaskill P., Irwig L., Moran R. & Bogduk N. (2009) Reliability of physical examination for diagnosis of myofascial trigger points; a systematic review of the literature. *The Clinical Journal of Pain* **25** (1), 80–89.
- Malbohan I. M., Mojžíšová L. & Tichý M. (1989) The role of coccygeal spasm in low back pain. *Journal of Manual Medicine* **7** (4), 140–141.
- Messelink B., Benson T., Berghmans B., et al. (2005) Standardization of terminology of pelvic floor muscle function and dysfunction: report from the pelvic floor clinical assessment group of the International Continence Society. *Neurourology and Urodynamics* **24** (4), 374–380.
- Montenegro M. L. L. de S., Mateus-Vasconcelos E. C., Candido dos Reis F. J., et al. (2010a) Thiele massage as a therapeutic option for women with chronic pelvic pain caused by tenderness of pelvic floor muscles. *Journal of Evaluation in Clinical Practice* **16** (5), 981–982.
- Montenegro M. L. L. de S., Mateus-Vasconcelos E. C. L., Rosa e Silva J. C., et al. (2010b) Importance of pelvic muscle tenderness evaluation in women with chronic pelvic pain. *Pain Medicine* **11** (2), 224–228.
- Oyama I. A., Rejba A., Lukban J. C., et al. (2004) Modified Thiele massage as therapeutic intervention for female patients with interstitial cystitis and high-tone pelvic floor dysfunction. *Urology* **64** (5), 862–865.
- Paradis H. & Marganoff H. (1969) Rectal pain of extrarectal origin. *Diseases of the Colon and Rectum* **12** (4), 306–312.
- Peters K. M., Carrico D. J., Kalinowski S. E., Ibrahim I. A. & Diokno A. C. (2007) Prevalence of pelvic floor dysfunction in patients with interstitial cystitis. *Urology* **70** (1), 16–18.
- Simons D. G., Travell J. G. & Simons L. S. (1999) *Travell & Simons' Myofascial Pain and Dysfunction: The Trigger Point Manual*, Vol. 1: *Upper Half of Body*, 2nd edn. Williams & Wilkins, Baltimore, MD.
- Slieker-ten Hove M. C. P., Pool-Goudzwaard A. L., Eijkmans M. J. C., et al. (2009) Face validity and reliability of the first digital assessment scheme of pelvic floor muscle function conform the new standardized terminology of the International Continence Society. *Neurourology and Urodynamics* **28** (4), 295–300.
- Thiele G. H. (1937) Coccygodynia and pain in the superior gluteal region and down the back of the thigh: causation by tonic spasm of the levator ani, coccygeus and piriformis muscles and relief by massage of these muscles. *The Journal of the American Medical Association* **109** (16), 1271–1275.
- Thiele G. H. (1963) Coccydynia: cause and treatment. *Diseases of the Colon and Rectum* **6** (6), 422–436.
- Tu F. F., Fitzgerald C. M., Kuiken T., Farrell T. & Harden R. N. (2007) Comparative measurement of pelvic floor pain sensitivity in chronic pelvic pain. *Obstetrics and Gynecology* **110** (6), 1244–1248.
- Tu F. F., Holt J., Gonzales J. & Fitzgerald C. M. (2008) Physical therapy evaluation of patients with chronic pelvic pain: a controlled study. *American Journal of Obstetrics and Gynecology* **198** (3), 272.e1–272.e7.
- Weiss J. M. (2001) Pelvic floor myofascial trigger points: manual therapy for interstitial cystitis and the urgency-frequency syndrome. *The Journal of Urology* **166** (6), 2226–2231.
- Whelan M. (2012) Practical anatomy, examination, palpation and manual therapy release techniques for the pelvic floor. In: *Chronic Pelvic Pain and Dysfunction: Practical Physical Medicine* (eds L. Chaitow & R. Lovegrove), pp. 311–338. Elsevier Churchill Livingstone, Edinburgh.

Maeve Whelan is in full-time private practice in urogynaecology, colorectal dysfunction and chronic pelvic pain in Dublin. She is a Specialist Chartered Physiotherapist, a title awarded by the Irish Society of Chartered Physiotherapists in 2008 and again in 2013. Maeve gained a Diploma in Obstetrics and Gynaecology in Physiotherapy from Trinity College Dublin in 1991. In 2013, she was awarded a Master of Science degree by the Royal College of Surgeons in Ireland for her research evaluating the effect of manual therapy and exercise on the levator plate in women with pelvic organ prolapse. Her special interest is the use of manual therapy in the treatment pelvic floor disorders.